

Pick RM, Mc Culum Y, Kaminsky EJ

~~J. Periodont. 56:492-496, 1985~~

Wound healing is accelerated by the sterilization of operating field, and swelling, wound contraction, and post-operative pain occurs only to a limited extent.

VIII. Prognosis

good

Potential Treatment Problems

1. Physiologic condition:OK

2. Psychologic condition:OK

Dental Anxiety;no

3. ~~Dental I. Q. :OK~~

4. Availability:OK

5. Finacial condition: **limited**

6. Others :no

About The Patient

1. Availability:OK
2. Financial status:limited
3. Psycho-social status:OK
4. Esthetic expectation:reasonable
5. Chewing function:OK
6. Individual tooth
problem:unesthetic ant. crowns

IX. Treatment Planning

Treatment Planning

Phase I

1. Consultation & motivation
2. OHI (Plaque control)
3. Perio initial therapy

Scaling + Root Planing + Lasing

Phase II: #s12,11,21,22 gingivoplasty with Lasersmile, #s11,21,22 provisional crowns fabrication

Phase III: #12 ceramic laminate, #s11,21,22 PFM

Phase IV Maintenance & 6-month recall

X. Treatment Procedures

Treatment Procedures :

1. 2002.07.03

Data collection , case presentation & OHI

2. 2002.07.09

Full mouth Scaling, #s12,11,21,22 de-epithelium with Lasersmile

3. 2002.07.13

#s12,11,21,22 Gingivoplasty with Lasersmile

4. 2002.07.20

#s11,21,22 Prep & Imp for PROV

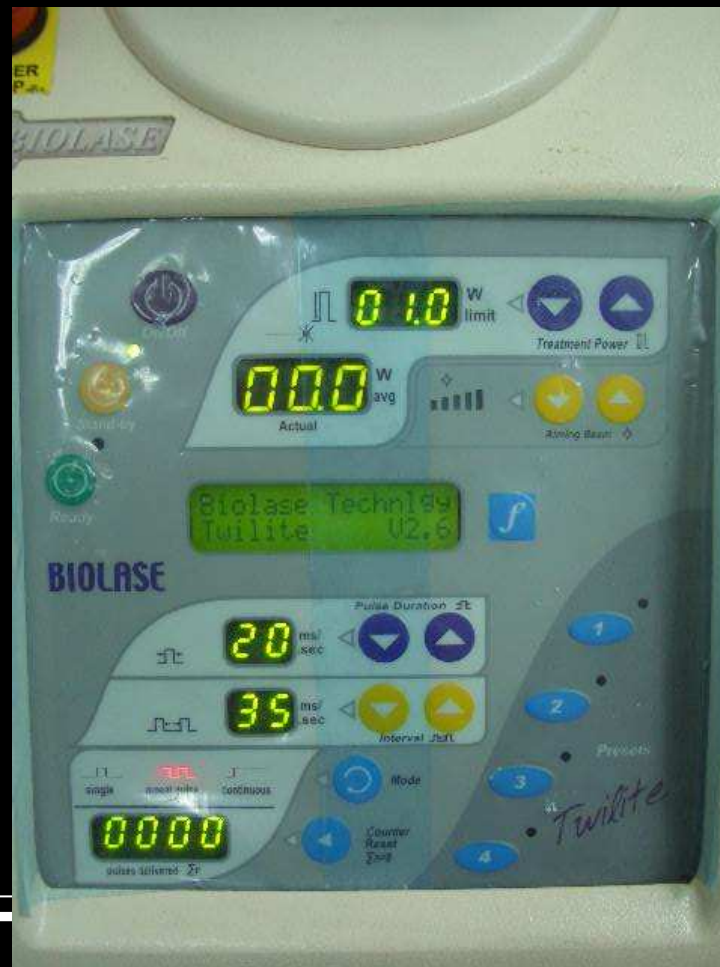
5. 2002.07.23

#s11,21,22 PROV insertion ; #s34,33,32,31,41,42,43,44 power bleach
with Lasersmile

6. 2002.11.08

#s11,21,22 Prep & Imp for porcelain crowns , #12 for veneer

De-epithelium



Gingivoplasty with water spray

